

See discussions, stats, and author profiles for this publication at: <https://www.researchgate.net/publication/328638422>

Ameliorative Effect of Methanol Extract of *Hymenocardia acida* Leaves on Gentamicin-Induced Renal Toxicity in Rats

Article in *Asian Journal of Biochemistry* · October 2018

DOI: 10.9734/AJRB/2018/44561

CITATIONS

0

READS

2,065

4 authors:



Nweje-Anyalowu Paul Chukwuemeka

Clifford University, Owerri, Abia State, Nigeria

55 PUBLICATIONS 132 CITATIONS

[SEE PROFILE](#)



Precious Adejoh Idakwoji

Prince Abubakar Audu University, Anyigba (PAAU) (formerly Kogi State University)

51 PUBLICATIONS 166 CITATIONS

[SEE PROFILE](#)



Lucky Osafanme Iserhienrhien

University of Benin

20 PUBLICATIONS 66 CITATIONS

[SEE PROFILE](#)



Anosike Joy

Godfrey Okoye University

8 PUBLICATIONS 22 CITATIONS

[SEE PROFILE](#)



Ameliorative Effect of Methanol Extract of *Hymenocardia acida* Leaves on Gentamicin-Induced Renal Toxicity in Rats

Nweje-Anyalowu Paul Chukwuemeka^{1*}, Idakwoji Precious Adejoh²,
Iserhienrhien Lucky Osafanme³ and Anosike Joy Chizoba⁴

¹Department of Biological Sciences, Biochemistry Section, Faculty of Science, Clifford University, Owerrinta, Abia State, Nigeria.

²Department of Biochemistry, Faculty of Natural Sciences, Kogi State University, Anyigba, Nigeria.

³Department of Biology, Faculty of Science, Nigeria Maritime University, Okerenkoko, Delta State, Nigeria.

⁴Department of Biochemistry, Faculty of Biological Sciences, University of Nigeria, Nsukka, Enugu State, Nigeria.

Authors' contributions

This work was carried out in collaboration between all authors. Author NAPC designed the study and wrote the protocol. Author IPA performed the statistical analysis and wrote the first draft of the manuscript. Authors ILO and AJC managed the analyses of the study and the literature searches. All authors read and approved the final manuscript.

Article Information

DOI: 10.9734/AJRB/2018/44561

Editor(s):

(1) Dr. Khadiga Mohamed Abu-Zied, Professor, Department of Photochemistry, National Research Centre, Cairo, Egypt.

Reviewers:

(1) Dennis Amaechi Biochemistry, Veritas University, Nigeria.

(2) Mhuji Kilonzo, The University of Dodoma, Tanzania.

Complete Peer review History: <http://www.sciencedomain.org/review-history/26950>

Original Research Article

Received 22 July 2018
Accepted 05 October 2018
Published 31 October 2018

ABSTRACT

Aim: This study evaluated the nephroprotective effect of methanol extract of *Hymenocardia acida* leaves in rat model of gentamicin induced renal damage.

Materials and Methods: Twenty- four (24) Wistar albino rats of either sex weighing 150- 200g were divided into 4 groups of 6 animals each; Group I served as the control and received normal saline, Group II- IV received gentamicin (40 mg/kg, i.p), Groups III and IV also received 200 and 400 mg/kg body wt., p.o methanol extract of *Hymenocardia acida* leaves respectively for 15 days. Body weight

*Corresponding author: E-mail: nwejeanyalowup@clifforduni.edu.ng;

measurement, serum urea, creatinine, electrolytes analyses and histopathological examination of kidney were carried out.

Results: Gentamicin treatment caused nephrotoxicity as evidenced by marked elevation in Serum urea, creatinine, decreased sodium and chloride ions, elevated serum level of potassium ion and pathological signs such as congestion, focal areas of inflammation, tubular necrosis, and glomerular atrophy. Administration of the extract at doses of 200 and 400 mg/kg/ body wt significantly ($p < 0.05$) decreased Creatinine and urea levels, significantly ($p < 0.05$) increased sodium and chloride ion and significantly ($p < 0.05$) decreased potassium ion level when compared to the gentamicin- alone-treated group. Histopathological analysis also revealed a gradual reversal of the pathological features caused by gentamicin toxicity.

Conclusion: It was concluded that the extract possesses nephroprotective potential.

Keywords: Gentamicin; *Hymenocardia acida*; renal; toxicity.

1. INTRODUCTION

Drug nephrotoxicity is one of the most common causes of acute kidney injury [1]. It occurs in 10–25% of patients treated with the therapeutic doses of aminoglycosides [2], especially gentamicin. The broad-spectrum activity against aerobic gram- positive and gram- negative organisms, their chemical stability and their rapid bactericidal action has made them the first-line drugs in a variety of clinical situations [3]. However, higher concentrations of these antibiotics are nephrotoxic. Gentamicin induced renal damage is widely used model for inducing nephrotoxicity in experimental animals [4]. It is characterised by direct tubular necrosis, which is localized mainly in the proximal tubules. It is a complex phenomenon characterised by an increase in plasma creatinine, urea levels, perturbed electrolyte balance, severe proximal tubular necrosis, followed by deterioration and renal failure [5,6]. The toxicity of gentamicin is thought to be related to the generation of reactive oxygen species (ROS) in the kidney [7]. Consequently, several compounds with antioxidant activity have been tested to ameliorate gentamicin nephrotoxicity.

Hymenocardia acida is a tree of about 6m high, gnarled and twisted with characteristics rough rusty-red bark, of the wooden savanna throughout the region from Senegal to west Cameroons, and widespread in tropical Africa. The wood is light brown or pink, darkening to orange, close- grained, with conspicuous annual rings, and hard. *Hymenocardia acida* (Euphorbiaceae) is very popular in African tradomedicine. It is called "Heart-fruit" in English [8]. It is commonly known as "*jan yaro*" in Hausa, "*ikalaga*" in Igbo, and "*Orunpa*" in Yoruba [9]. In Senegal and Ivory Coast, an infusion or decoction of its leaves is used for the treatment

of chest complaints, small pox, in baths and draughts as a febrifuge, and is taken as snuff for headaches or applied topically for rheumatic pains and toothaches [10]. The bark and leaves are used together in various ways in Nigeria for abdominal and menstrual pains and as poultices on abscesses and tumours. The powdered leaves of the plant are used for the treatment of arthritis [11]. Studies have also shown that *H. acida* possesses free radical scavenging activity and strong reducing power *in vitro* [12]. Phytochemical screening of this plant revealed the presence of flavonols, flavonoids, phenols, proanthocyanidins, steroids and triterpenoids which are likely to be responsible for its antioxidant properties [10]. Based on the reported anti- oxidant activity of *H. acida*, this study investigated the possible protective effect of the methanol extract of the leaves of the plant against Gentamicin- induced nephrotoxicity in albino Wistar rats.

2. MATERIALS AND METHODS

2.1 Materials

2.1.1 Chemicals and drugs

Gentamicin was purchased from 'Good Shepherd' Pharmacy Shop, Mararaba, Nassarawa, Nigeria. All the other chemicals (Methanol, sulfuric acid and sodium hydroxide) used were of analytical grade and were purchased from Sigma- Aldrich through a local vendor.

2.1.2 Animals

Adult Wistar rats of either sex weighing 150–200g were used for this study. They were kept in stainless steel cages under standard laboratory

conditions. They were maintained on clean water and standard rodent feed.

2.2 Methods

2.2.1 Plant collection and identification

The leaves of *Hymenocardia acida* were collected from a natural habitat in Mararaba Area of Nassarawa State, Nigeria. The plants were identified at the herbarium unit of Biological Sciences Department, Nassarawa State University, Keffi and voucher specimen (voucher number HA076) was deposited for future references.

2.2.2 Preparation of extracts

The leaves of *Hymenocardia acida* were shade-dried for seven (7) days and pulverised using an electric blender. Two thousand and five hundred (2500) gram of the pulverised leaves was cold macerated in methanol for 72 hours. The resulting mixture was filtered using Whatmann filter paper (Size No1) and the extract was concentrated using rotary evaporator. The extract will from now on be referred to as Methanolic Extract of *Hymenocardia acida* (MEHA).

2.2.3 Acute toxicity study

The oral median lethal dose (LD₅₀) of the extract was determined in rats according to the method of [13].

2.2.4 Experimental design

After an acclimatisation period of Seven (7) days, twenty- four (24) albino rats were divided into four groups of six animals each and treated as follows:

- Group I: Control (1ml normal saline)
- Group II: Gentamicin (40mg/kg)
- Group III: Gentamicin (40mg/kg) + MEHA (200mg/kg)
- Group IV: Gentamicin (40mg/kg) + MEHA (400mg/kg)

Except group I animals, other three groups received 40 mg/kg/ day gentamicin intraperitoneally while the extract was administered orally to Groups 3 and 4 rats. All treatments were carried out for a period of fifteen (15) days after which blood and tissue (kidney) samples were collected for biochemical and

histopathological analyses respectively. The parameters monitored are as follows:

2.2.4.1 Body weight

Body weights of these rats were monitored every 3 days within the period of treatment.

2.2.4.2 Serum creatinine

Creatinine was estimated using the method described previously by Broad and Sirota, using Jaffe's reaction. To 1.0mL of serum and kidney homogenates, 8.0 ml of double-distilled water, 0.5mL of 2/3N sulfuric acid and 0.5ml of 10% sodium tungstate were added. This mixture was centrifuged at 4000 rpm for 15 min at 4 °C, 5.0ml of the clear supernatant was taken to which 1.5ml of saturated picric acid and 1.5ml of 0.75N sodium hydroxide were added. The absorbance was read at 460 nm after 15mins. Standard and blank were also processed similarly.

2.2.4.3 Urea estimation

Urea was estimated by method reported by [14]. Urea was estimated by the reported method. To 0.1ml of serum and kidney homogenates, 3.3ml of double-distilled water, 0.3ml of 10% sodium tungstate and 0.3mL of 0.67N sulfuric acids were added. The samples were centrifuged (4000 rpm, 15 min, 4°C) and to 1ml of the supernatant, 1ml of double-distilled water, 0.4ml of diacetyl monoxime reagent and 0.6ml of sulfuric acid-phosphoric acid mixture were added. The samples were incubated in a boiling water bath for 30 min, cooled to room temperature and the absorbance was read at 480 nm.

2.2.4.4 Serum electrolytes

The Sodium and Potassium ions concentration was determined using Flame Photometric method. Compressed air, diluted serum (1 in 20 dilutions) was sprayed as a fine mist of droplets (nebulised) into a non-luminous gas flame which became coloured by the characteristics emission of the sodium or potassium metallic ions in the sample. Light of a wavelength corresponding to the metal being measured (sodium- 589nm; potassium-767nm) was selected by a light filter and allowed to fall on a photosensitive detector system. The amount of light emitted depends on the concentration of metallic ions present. By comparing the amount of light emitted from the sample with that from a standard solution, the amount of electrolyte in the sample was measured.

2.2.4.5 Histopathological examination

The kidneys were excised and quickly fixed in 10% formalin, processed and stained with haematoxylin and eosin and then observed under microscope for degeneration, fatty changes, necrotic changes and evidence of nephrotoxicity.

2.2.5 Statistical analysis

Statistical analysis was carried out using SPSS version 20.0. All the data were expressed as mean \pm SEM and the statistical differences between the means were determined by one way analysis of variance (ANOVA) which was followed by Duncan test and difference between means at $P > 0.05$ were considered significant.

3. RESULTS

3.1 Acute Toxicity

The results of acute toxicity studies showed no mortality or physical changes, circulatory signs, autonomic and central nervous system effects up to a dose of 5000 mg/kg of methanol extract of *Hymenocardia acida*. The oral LD₅₀ of the extract was therefore taken to be > 5000 mg/kg.

3.2 Effect of the Administration of Methanol Extract of *Hymenocardia acida* Leaves (MEHA) on the Body Weight of Rats

As shown in Table 1, no significant ($p > 0.05$) changes were observed in the body weights of the Gentamicin- alone (Group I) and Gentamicin/ extract- treated groups (Groups III and IV) compared to the normal control (Group I).

3.3 Effect of the Administration of Methanol Extract of *Hymenocardia acida* Leaves (MEHA) on Serum Creatinine and Urea Levels of Rats

The effect of treatment on serum creatinine and urea levels of rats is shown in Figures 1 and 2. Gentamicin- alone- treated group (Group II) showed significant ($p < 0.05$) increase in both creatinine and urea levels when compared to normal control (Group I). However, administration of methanol extract of *Hymenocardia acida* leaves at doses of 200 and 400mg/kg (Groups III and IV) alongside Gentamicin produced significant ($p > 0.05$) reduction in both creatinine and urea levels when

compared to the Gentamicin- alone- treated group (Group II).

3.4 Effect of the Administration of Methanol Extract of *Hymenocardia acida* Leaves (MEHA) on Serum Electrolytes of Rats

The Gentamicin- alone- treated group showed significant ($p \leq 0.05$) decrease in serum Na⁺ and Cl⁻ levels with a significant ($p \leq 0.05$) increase in K⁺ level when compared to the normal control (Table 2). However, administration of methanol extract of *Hymenocardia acida* leaves at doses of 200 and 400mg/kg (Groups III and IV) alongside Gentamicin significantly ($p > 0.05$) increased the serum levels of Na⁺ and Cl⁻ and significantly ($p > 0.05$) reduced serum K⁺ level compared to the Gentamicin- alone- treated group (Group II).

3.5 Histopathological Findings

Histopathological examination of the kidney tissue of the control group showed normal glomeruli, intact Bowman's capsule and proximal convoluted capsule (Plate 1). Gentamicin- treated group showed severe glomerular congestion, inflammatory cells, necrosis and tubular casts (Plate 2). Administration of 200 mg/kg methanol extract of *Hymenocardia acida* leaves alongside Gentamicin showed mild reduction in glomerular congestion, inflammatory cells, necrosis and tubular casts (Plate 3) while administration of 400 mg/kg of the extract showed near normalisation of the kidney architecture (Plate 4).

4. DISCUSSION

Nephrotoxicity is the most important side effect associated with the consumption (for more than 7 days) of aminoglycoside antibiotics such as gentamicin. The prevalence of this complication is over 30%. It brings about the incidence of 10%- 20% of acute renal failure [15,16,17]. However, different prescribing options can have a variety of implications [18]. The most common symptoms of nephrotoxicity include decreased glomerular filtration, increased creatinine, blood urea nitrogen (BUN), uric acid, alkaline phosphatase, and electrolyte changes [19,20]. This study evaluated the possible protective effect of the methanol extract of *Hymenocardia acida* leaves against Gentamicin induced nephropathy in rats.

Body weight of rats was monitored as a reduction in body weight is usually one of the

manifestations of Gentamicin- induced-nephrotoxicity. In this study, no significant changes were observed when the group administered Gentamicin alone and Gentamicin/ extract groups were compared to the control. This is contrary to the findings of other researchers as weight loss usually accompanies gentamicin- induced nephrotoxicity.

The increased creatinine levels in the serum of the Gentamicin- treated rats is as a result of a decrease in glomerular filtration rate (GFR) and creatinine filtration that is associated with kidney damage [21]. There is usually an increase in

serum urea level when its rate of production surpasses its rate of elimination [22,23]. The increase in urea is therefore also an indication of renal damage. This study showed a statistical significant elevation in serum urea, creatinine (Figs. 1 and 2) following gentamicin administration. The methanol extract of *Hymenocardia acida* at both doses however significantly reduced the levels of these markers indicating its ability to protect the kidney from damage due to gentamicin possibly by improving the ability of the glomerulus to filter urea and creatinine.

Table 1. Effect of the administration of methanol extract of *Hymenocardia acida* leaves (MEHA) on the body weight of rats

Group	days (d)					
	0	3	6	9	12	15
Group 1	168.3±13.45	168.9±20.13	171.4±10.28	174.6±11.18	176.5±09.12	177.3±12.14
Group 2	165.1±15.64	167.5±19.11	172.9±13.81	174.2±13.11	178.3±13.15	178.9±10.61
Group 3	166.3±18.20	170.4±18.01	173.2±12.13	175.4±18.19	177.8±20.17	178.3±12.14
Group 4	167.5±21.15	169.5±20.43	171.2±13.18	173.8±10.13	179.4±21.15	180.5±18.11

Data are presented as mean ± SD of body weight (g). Data was analysed by one- way ANOVA followed by Duncan post- hoc test for multiple comparisons, (n=6). Mean values having different lower case alphabets as superscripts are considered significant ($p < 0.05$) across the columns. Group 1: Control received Normal saline. Group 2: received 40 mg/ kg Gentamicin. Group 3: received 40 mg/kg Gentamicin + 200 mg/ kg MEHA. Group 4 received 40 mg/ kg Gentamicin + 400 mg/ kg MEHA

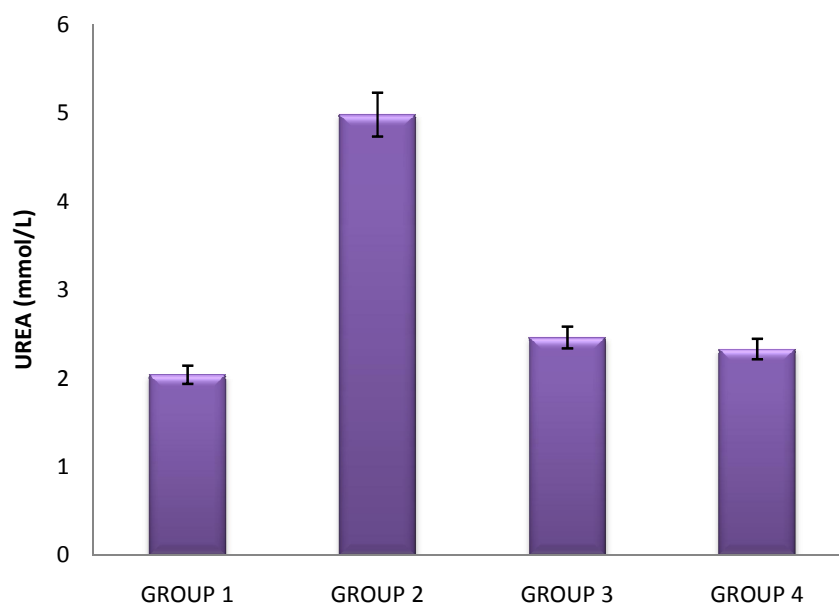


Fig. 1. Effect of the administration of methanol extract of *Hymenocardia acida* leaves (MEHA) on serum urea levels of rats

Group 1: Control received 1ml Normal saline. Group 2: received 40 mg/ kg Gentamicin. Group 3: received 40 mg/kg Gentamicin + 200 mg/ kg MEHA. Group 4 received 40 mg/ kg Gentamicin + 400 mg/ kg MEHA

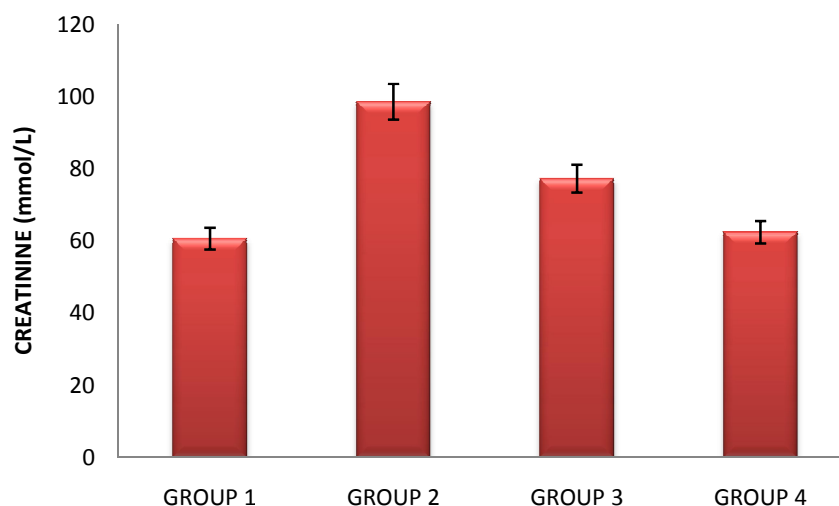


Fig. 2. Effect of the administration of methanol extract of *Hymenocardia acida* leaves (MEHA) on serum creatinine levels of rats

Group 1: Control received 1ml Normal saline. Group 2: received 40 mg/ kg Gentamicin. Group 3: received 40 mg/kg Gentamicin + 200 mg/ kg MEHA. Group 4 received 40 mg/ kg Gentamicin + 400 mg/ kg MEHA

Table 2. Effect of the administration of methanol extract of *Hymenocardia acida* leaves (MEHA) on serum electrolytes of rats

Treatment	K ⁺ (μmol/L)	Na ⁺ (μmol/L)	Cl ⁻ (μmol/L)
Group 1	3.75±0.13 ^a	135.1±4.56 ^b	101.5±1.12 ^b
Group 2	6.15±0.45 ^b	109.0±2.46 ^a	89.3±2.26 ^a
Group 3	3.92±0.54 ^a	139.4±7.16 ^b	103.4±6.91 ^b
Group 4	3.79±0.14 ^a	139.6±2.32 ^b	102.6±8.56 ^b

Data are presented as mean ± SD. Data was analysed by one- way ANOVA followed by Duncan post- hoc test for multiple comparisons, (n=6). Mean values having different lower case alphabets as superscripts are considered significant ($p < 0.05$) across the columns. Group 1: Control received 1normal saline. Group 2: received 40 mg/ kg Gentamicin. Group 3: received 40 mg/kg Gentamicin + 200 mg/ kg MEHA. Group 4 received 40 mg/ kg Gentamicin + 400 mg/ kg MEHA

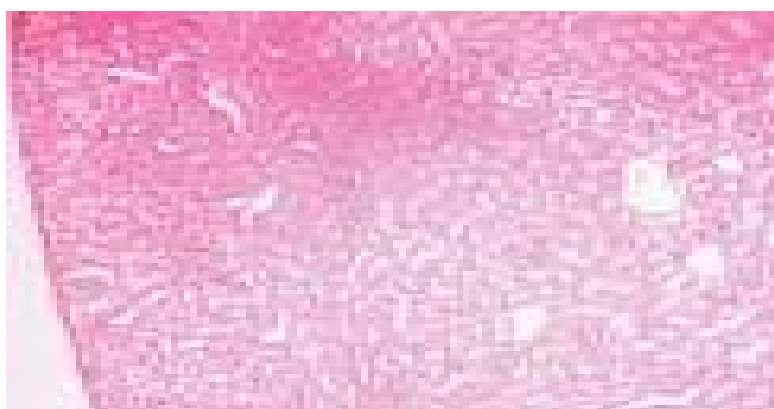

Plate 1. Micrograph showing Kidney tissue of control rat with normal glomeruli, intact Bowman's capsule and proximal convoluted capsule (H and E stain, Mg. × 40)

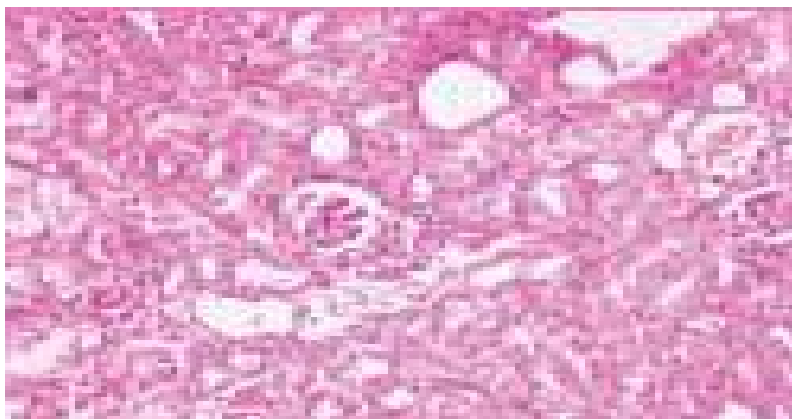


Plate 2. Photomicrograph of the Kidney tissue of a rat treated with Gentamicin showing glomerular congestion, inflammatory cells, necrosis and tubular casts (H and E stain, Mg. × 200)

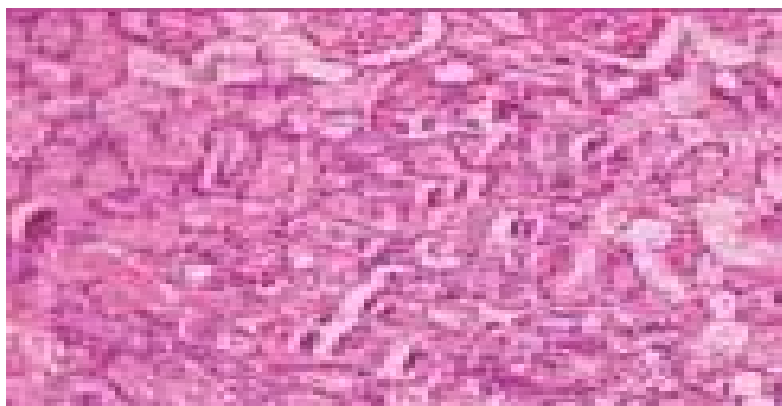

Plate 3. Photomicrograph of the Kidney tissue of a 200mg /kg MEHA-treated rat showing decreasing glomerular congestion, inflammatory cells, necrosis and tubular casts (H and E stain, Mg. × 800)



Plate 4. Photomicrograph of the Kidney tissue of a 400mg /kg MEHA -treated rat showing normal arrangement of cells (H and E stain, Mg. × 100)

Our result also suggests that methanol extract of *Hymenocardia acida* leaves prevents the decline in serum electrolyte concentrations associated with Aminoglycosides. The lower value of serum

sodium observed with the Gentamicin- alone treated group indicated the inability of the kidney to conserve sodium and chloride. Haemodilution too may be involved in the fall of sodium value via excess of water intake and or increased production of endogenous water. The increase in the level of Potassium may be due to its reduced excretion aggravated by leakage of intracellular potassium into blood stream as a result of gentamicin induced lesions in the renal tubular epithelium. The present results are in harmony with the data obtained by [24] and [25]. Apoptosis plays a major role in kidney embryogenesis, resulting in large-scale cell death during development [26]. By contrast, in the adult and under normal circumstances, evidence of apoptosis is seldom found in the kidney, where the rate of cell turnover is very low. However, there are a number of documented cases related to kidney insult in both pathology and toxicology where the renal tissue, in particular the tubular epithelium, exhibits a substantial increase of apoptotic cells [27,28]. The extract at doses of 200 and 400mg/kg was able to return the levels of the electrolytes to near normal.

Histopathological examination of the kidney tissues revealed various pathological signs such as congestion, focal areas of inflammation, tubular necrosis, and glomerular atrophy in the gentamicin- alone treated group. The extract at the doses administered was able to reverse some of these observations. This observation further proves the nephro- protective effect of the extract.

5. CONCLUSIONS

Our findings have provided strong evidence that methanol extract of *Hymenocardia acida* leaves possesses protective effects against gentamicin-induced nephrotoxicity in rats. This protective effect might be due to its reported antioxidant and anti-inflammatory properties or other pathways which require further studies.

ETHICAL APPROVAL

As per international standard or university standard written ethical approval has been collected and preserved by the author(s).

COMPETING INTERESTS

Authors have declared that no competing interests exist.

REFERENCES

1. Binswanger U. Acute renal failure: Changing causes? *Kidney Blood Press Res.* 1997;2(20):163.
2. Lopez-Novoa JM, Quiros Y, Vicente L, Morales AI, Lopez-Hernandez FJ. New insights into the mechanism of aminoglycoside nephrotoxicity: An integrative point of view. *Kidney Int.* 2011;79:33–45.
3. Martı́nez-Salgado C, Lo’pez-Herna’ndez FJ, Lo’pez-Novoa JM. Glomerular nephrotoxicity of aminoglycosides. *Toxicol Appl Pharmacol.* 2007;223:86–98.
4. El Mouedden M, Laurent G, Mingeot-Leclercq MP, Taper HS, Cumps J. Apoptosis in renal proximal tubules of rats treated with low doses of aminoglycosides. *Antimicrob Agents Chemother.* 2000;44: 665–675.
5. Edwards JR, Diamantakos EA, Peuler JD, Lamar PC, Prozialeck WC. A novel method for the evaluation of proximal tubule epithelial cellular necrosis in the intact rat kidney using ethidium homodimer. *BMC Physiol.* 2007;7:1–14.
6. Bledsoe G, Crickman S, Mao J, Xia C, Murakami H. Kallikrein-kinin protects against gentamicin-induced nephrotoxicity by inhibition of inflammation and apoptosis. *Nephrol Dial Transplant.* 2006;21:624–633.
7. Ali BH, Al Zaabi M, Blunden G, Nemmar AI. Experimental Gentamicin nephrotoxicity and agents that modify it: A mini-review of recent research. *Basic Clin Pharmacol Toxicol.* 2011;109:225-232.
8. Schmelzer GH. Hymenocardia acida tul. In: G H Schmelzer, and A Gurib-Fakim (Editors). *Prota 11(1): Medicinal plants/ plantes medicinales 1.* [CD-Rom]. 2008, PROTA, Wageningen, Netherlands.
9. Ibrahim H, Sani FS, Danladi BH, Ahmadu AA. *Pakistan J. Biol. Sci.* 2007;10(5):788-791.
10. Sofidiya MO, Odukoya OA, Afolayan AJ, Familoni OB. Phenolic contents, antioxidant and antibacterial activities of *Hymenocardia acida*. *Nat Prod Res.* 2009; 23:168-177.
11. Burkhill HM. *Useful plants of West Tropical Africa* Kew, England: Families E-I. Royal Botanical Gardens. 1994;2:85.
12. Sofidiya MO, Odukoya OA, Familoni OB, Inya-Agha SI. Free radical scavenging activity of some Nigerian medicinal plants. *Pak J Bio Sc.* 2006;9:1438-1441.

13. Lorke, D. A new approach to practical acute toxicity testing. Archives of Toxicology. 1983;54:275-287.
14. Natelson S, Scott ML, Beffa C. A rapid method for the estimation of urea in biologic fluids. Am J Clin Pathol. 1951;21: 275-281.
15. Balakumar P, Rohilla A, Thangathirupathi A. Gentamicin-induced nephrotoxicity: Do we have a promising therapeutic approach to blunt it? Pharmacol Res. 2010;62:179-86.
16. Ali BH, Za'abi A, Blunden G, Nemmar A. Experimental gentamicin nephrotoxicity and agents that modify it: a mini-review of recent research. Basic Clin Pharmacol Toxicol. 2011;109:225-32.
17. Tavafi M, Ahmadvand H, Goodarzi S, Rasouljan B. Investigating the effect of pretreatment with oxygen on inhibition of gentamycin-induced nephrotoxicity in rats. JSSU. 2013;21:523-532
18. Kim S, LeshnerPerez SC, Yamanishi C, Labuz JM, Leung B, Takayama S. Pharmacokinetic profile that reduces nephrotoxicity of gentamicin in a perfused kidney-on-a-chip. Biofabrication. 2016;8: 015021.
19. Lopez-Novoa JM, Quiros Y, Vicente L, Morales AI, Lopez-Hernandez FJ. New insights into the mechanism of aminoglycoside nephrotoxicity: An integrative point of view. Kidney Int. 2011;79:33-45.
20. Nasri H, Nematbakhsh M, Rafieian-Kopaei M. Ethanolic extract of garlic for attenuation of gentamicin-induced nephrotoxicity in Wistar rats. Iran J Kidney Dis. 2013;7:376-82.
21. Gowda KS, Swamy BV. Histopathological and nephroprotective study of aqueous stem bark extract of *Ficus racemosa* in drug induced nephrotoxic rats. IOSR J Pharm. 2012;2(2):265-270.
22. Kishor K, Singh M. Effect of becosides, an alcoholic extract of *Bacopa monnieri* amnesia in mice. Indian J of Exper Biol. 2005;43:640-5.
23. Mayne PD. The kidneys and renal calculi. In: Clinical chemistry in diagnosis and treatment. 6th ed. London: Edward Arnold Publications. 1994;2-24.
24. Heibashy MIA. and Abdel Moneim, AE. Kidney and liver function tests after late Dimethyl sulfoxide (DMSO) administration in rats with gentamicin induced acute renal failure. J. Egypt. Ger. Soc. Zool. 1999;30(A):35-48.
25. Heibashy MIA, El-Nahla AM, Ibrahim AI, Saleh Sh. YA. Comparative study between dimethyl sulfoxide (DMSO), allopurinol and urate oxidase administration in nephrotoxic rats induced with gentamicin. 43rd Annual Veterinary Medical Symposium, College of Veterinary Medicine Nursing and Allied Health, Tuskegee University, Alabama, USA; 2009.
26. Coles HSR, Burne JF, Raff MC. Large scale normal cell death in the developing rat kidney and its reduction by epidermal growth factor. Development. 1993;118: 777-784.
27. Conaldi PG, Biancone L, Bottelli A, Wade-Evans A, Racusen LC, Boccellino M, Toniolo A. HIV-1 kills renal tubular epithelial cells in vitro by triggering an apoptotic pathway involving caspase activation and Fas upregulation. J Clin Investig. 1998;102:2041-2049.
28. Davis MA, Ryan DH. Apoptosis in the kidney. Toxicol Pathol. 1998;26:810-825.

© 2018 Nweje et al.; This is an Open Access article distributed under the terms of the Creative Commons Attribution License (<http://creativecommons.org/licenses/by/4.0>), which permits unrestricted use, distribution, and reproduction in any medium, provided the original work is properly cited.

Peer-review history:
The peer review history for this paper can be accessed here:
<http://www.sciencedomain.org/review-history/26950>